

# Fluid Distribution Patterns in Early-Stage Upper Extremity Lymphedema

Rosie Friedman, BS,<sup>a</sup> Clarissa Lee,<sup>b</sup> Jacquelyn R. Kinney, BA,<sup>a</sup> Betsa Parsai Salehi, MD,<sup>b</sup> Geunwon Kim, MD, PhD,<sup>c</sup> Dhruv Singhal, MD,<sup>a</sup> and Leo L. Tsai, MD, PhD, MSc<sup>b</sup>

**Introduction:** Magnetic resonance imaging (MRI) stage 1 (early stage) upper extremity lymphedema is characterized by fluid infiltration in the subcutaneous tissues that does not exceed 50% of the extremity circumference at any level. The spatial fluid distribution in these cases has not been detailed and may be important to help determine the presence and location of compensatory lymphatic channels. The aim of this study is to determine whether there was a pattern of distribution of fluid infiltration in patients with early-stage lymphedema that could correspond to known lymphatic pathways in the upper extremity.

**Methods:** A retrospective review identified all patients with MRI stage 1 upper extremity lymphedema who were evaluated at a single lymphatic center. Using a standardized scoring system, a radiologist graded the severity of fluid infiltration at 18 anatomical locations. A cumulative spatial histogram was then created to map out regions where fluid accumulation occurred most and least frequently.

**Results:** Eleven patients with MRI stage 1 upper extremity lymphedema were identified between January 2017 and January 2022. The mean age was 58 years and the mean BMI was 30 m/kg<sup>2</sup>. One patient had primary lymphedema and the remaining 10 had secondary lymphedema. The forearm was affected in nine cases, and fluid infiltration was predominantly concentrated along the ulnar aspect, followed by the volar aspect, while the radial aspect was completely spared. Within the upper arm, fluid was primarily concentrated distally and posteriorly, and occasionally medially.

**Conclusions:** In patients with early-stage lymphedema, fluid infiltration is concentrated along the ulnar forearm and the posterior distal upper arm, which aligns with the tricipital lymphatic pathway. There is also sparing of fluid accumulation along the radial forearm in these patients, suggesting a more robust lymphatic drainage along this region, possibly due to a connection to the lateral upper arm pathway.

**Key Words:** lymphedema, edema distribution, lymphatics

(*Ann Plast Surg* 2023;00: 00–00)

Upper extremity lymphedema results from insufficiency of the lymphatic system. Patients present with swelling and decreased mobility, which can severely diminish quality of life. Untreated lymphedema

is typically progressive and can lead to increased edema and fat hypertrophy and continued limb enlargement. Despite the expected course of disease progression, there is considerable variation in the severity of disease at the time of initial presentation with some patients presenting with relatively mild manifestations or even in a subclinical stage of limb swelling.<sup>1–3</sup> There are multiple ways to evaluate or grade upper extremity lymphedema including bioimpedance, circumferential measurements, and perometry. As magnetic resonance imaging (MRI) is able to differentiate soft tissues, lymphedema can more be objectively graded using an MRI grading system to determine the extent of the fluid component within the extremity.<sup>4,5</sup> While the severity of edema can be defined using this grading system, spatial patterns of fluid distribution along the affected extremity in those with primary and secondary upper extremity lymphedema have not been well studied.

During the validation of an MRI grading system, one group previously noticed a general pattern of fluid infiltration along the elbow and the posterior aspect of the upper arm.<sup>4</sup> In another study, the authors examined edema distribution patterns in patients with breast cancer–related lymphedema and noted that areas spared from edema were centered around the cephalic vein in the upper arm.<sup>6</sup> However, a study on patients with lower extremity lymphedema did not observe any consistent patterns in fluid distribution in lymphedematous extremities.<sup>7</sup> There have been no prior studies focusing on edema distribution patterns, particularly at early stages before these patterns become indistinguishable because of more diffuse edema.

Knowledge of the spatial patterns of edema in lymphedema may reveal areas of lymphatic vulnerability. Furthermore, disease-free areas may reflect zones of compensated or more robust drainage.<sup>6</sup> The purpose of this study was to determine these patterns of edema in the upper extremities of patients with early-stage lymphedema.

## METHODS

A retrospective review of our MRI lymphatic center database was performed. Institutional review board approval was obtained (protocol # 2018P000085). Consecutive patients with MRI stage 1 upper extremity lymphedema were identified using a previously validated MRI staging system.<sup>4</sup> Briefly, MRI stage 1 upper extremity lymphedema was defined by fluid infiltration in the subcutaneous tissue that did not exceed 50% of the circumference of the forearm or upper arm at any level.<sup>4</sup>

Patient demographics were extracted from the lymphatic center database and MRI reports were reviewed to identify all patients with MRI stage 1 upper extremity lymphedema. Using a standardized scoring system, an attending radiologist with fellowship training in MRI (L.L.T.) graded the severity of fluid infiltration at 5 levels along the hand, forearm, and upper arm, across a total of 18 anatomical locations (Fig. 1). Grades of 0 to 3 were assigned based on the severity of edema in that region with grade 0 being no edema, grade 1 being less than 25% fluid by volume across the subcutaneous fat or with dermal thickening only, grade 2 between 25% and 50% fluid by volume, and grade 3 indicating greater than 50% fluid by volume. Data were analyzed in Microsoft Excel (Microsoft 2021, Redmond, Wash). A histogram was generated and the cumulative score across all patients was calculated at each anatomic location and

Received December 15, 2022, and accepted for publication, after revision December 31, 2022.

From the <sup>a</sup>Division of Plastic and Reconstructive Surgery, Department of Surgery, Beth Israel Deaconess Medical Center, Harvard Medical School, and <sup>b</sup>Department of Radiology, Beth Israel Deaconess Medical Center, Harvard Medical School, Boston; and <sup>c</sup>Atrius Health, Newton, MA

Conflicts of interest and sources of funding: none declared.

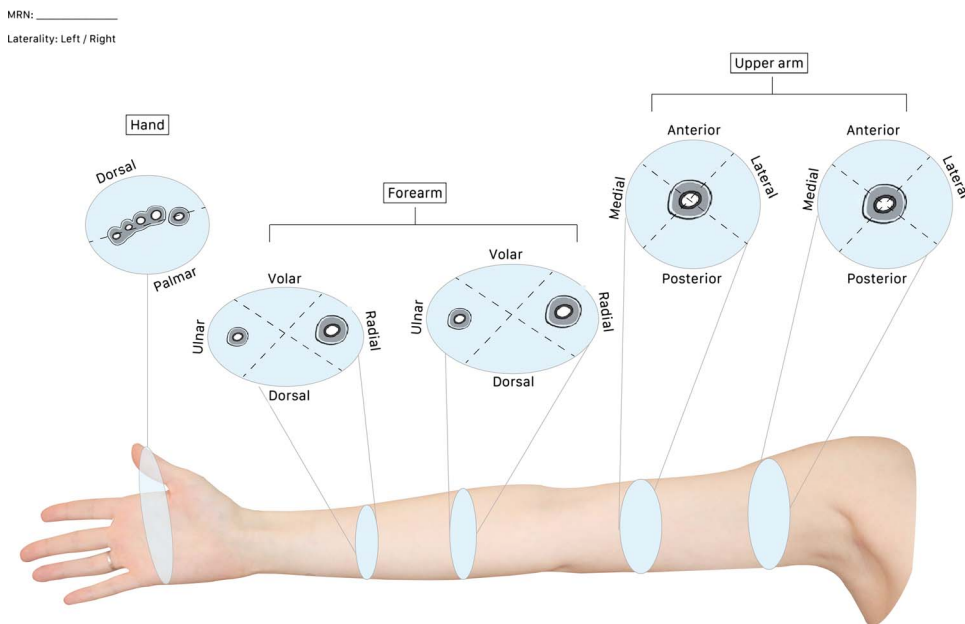
Research reported in this publication was partially supported by the National Heart, Lung, and Blood Institute of the National Institutes of Health (<https://www.nih.gov/>) under Award Number R01HL157991, and the Radiological Society of North America under Award RR1820. R.F. is sponsored by the 2022 JOBST Lymphatic Research Grant awarded by the Boston Lymphatic Symposium, Inc. The authors are accountable for all aspects of the work in ensuring that questions related to the accuracy or integrity of any part of the work are appropriately investigated and resolved. This study was institutional review board approved 2018-P-000085 at Beth Israel Deaconess Medical Center.

Reprints: Leo L. Tsai, MD, PhD MSc, Division of MRI, Beth Israel Deaconess Medical Center, 330 Brookline Ave, ANSIN 230, Boston, MA 02215. E-mail: [tsai1@bidmc.harvard.edu](mailto:tsai1@bidmc.harvard.edu).

Copyright © 2023 Wolters Kluwer Health, Inc. All rights reserved.

ISSN: 0148-7043/23/0000-0000

DOI: 10.1097/SAP.0000000000003494



**FIGURE 1.** Scoring sheet used to grade the severity of fluid infiltration at 5 levels along the extremity scored from 0 to 3, with 0 indicating the absence of fluid infiltration and 3 reflecting severe fluid infiltration.

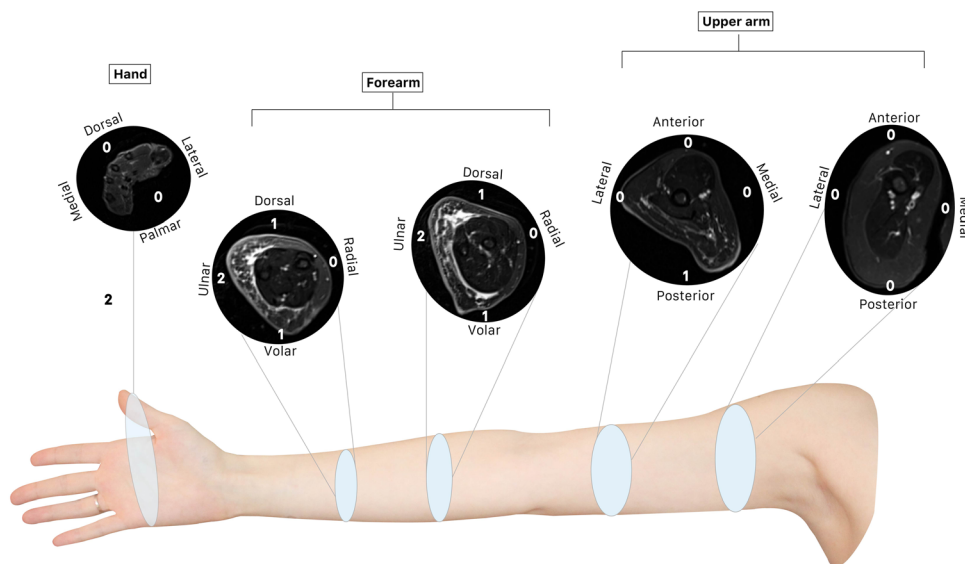
visualized using a radar chart to display the spatial distribution of edema cumulatively across all subjects.

**RESULTS**

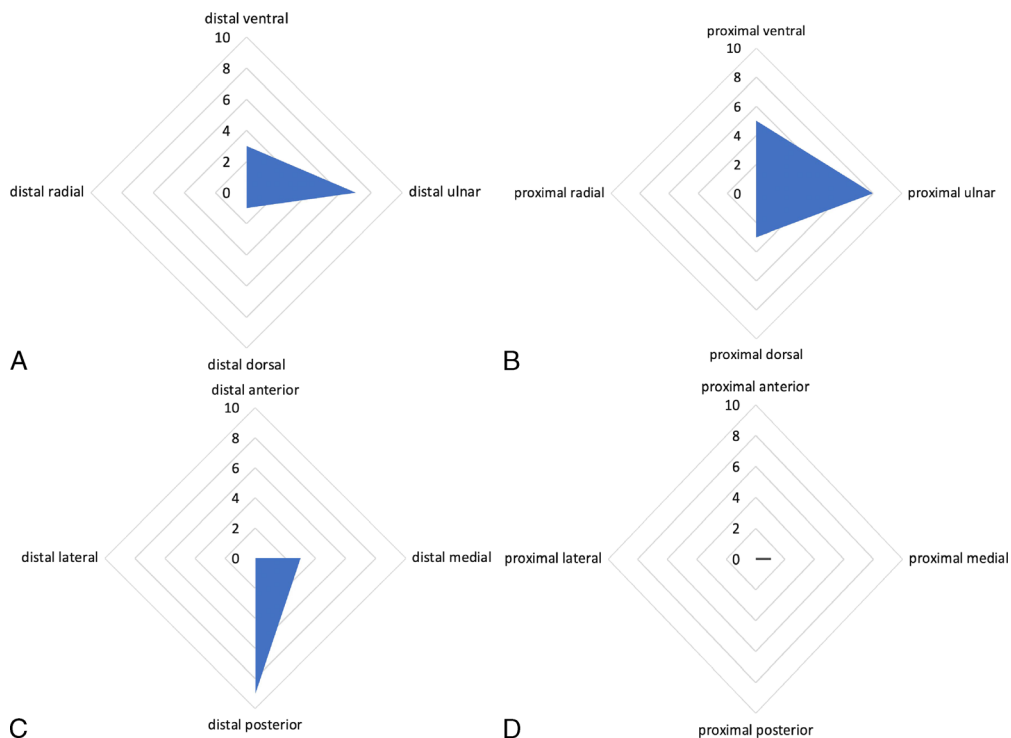
Eleven patients with MRI stage 1 upper extremity lymphedema were identified between January 2017 and January 2022. Ten patients (91%) were female, and one patient was male (9%). The average age of the overall cohort was 58 years, and the average BMI was 30 m/kg<sup>2</sup>. One patient (9%) had primary upper extremity lymphedema and the remaining 10 patients (91%) had secondary lymphedema. Of those with

secondary lymphedema (n = 10), 8 had breast cancer–related lymphedema, 1 developed lymphedema after an episode of cellulitis, and 1 patient developed lymphedema after cosmetic breast reconstruction and brachioplasty. The average symptom duration of the cohort was 6.4 years.

An example case is shown in Figure 2. Graphical representations of edema distribution are shown in Figure 3. The hand was completely spared in all cases but one. The forearm was affected in 9 cases (82%). Along the forearm, fluid infiltration both proximally and distally was concentrated in the ulnar forearm and, to a lesser extent, the volar forearm. Notably, in all 11 cases (100%), the radial forearm was entirely unaffected. In the distal upper arm, fluid was primarily concentrated



**FIGURE 2.** Example of fluid scoring on axial T2-weighted fat-suppressed MR images obtained at the 5 measured levels along the upper extremity in a patient with right upper extremity lymphedema.



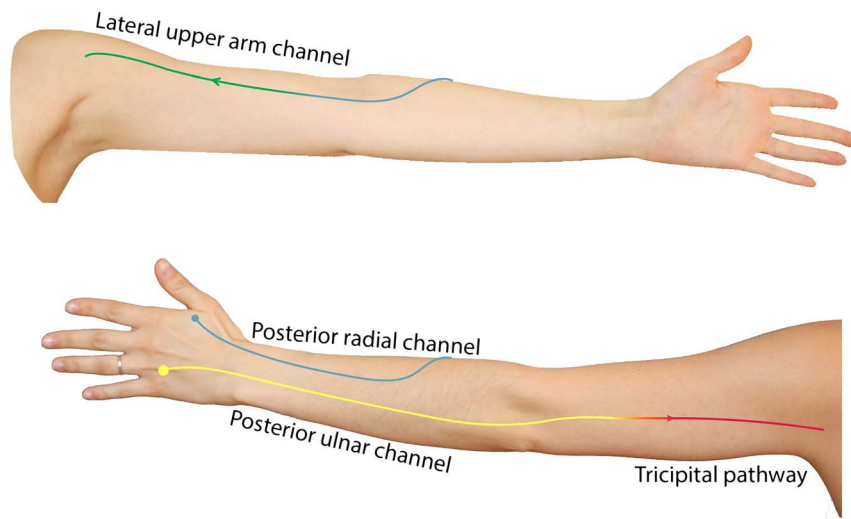
**FIGURE 3.** The distribution of edema at the level of the distal forearm (A), proximal forearm (B), distal upper arm (C), and proximal upper arm (D).

posteriorly and occasionally present medially. The proximal upper arm was only involved in one case, in which fluid was present medially.

**DISCUSSION**

In this study, we characterized spatial distribution of fluid in patients with MRI stage 1 upper extremity lymphedema. Fluid infiltration was concentrated in the ulnar forearm and the posterior distal upper arm, and with complete sparing of the radial forearm.

In all cases (n = 11), the radial forearm was spared from edema. One possible explanation is a more robust lymphatic drainage at this location. We have previously observed that the radial forearm lymphatic channels are more likely to have a functional connection to the lateral upper arm pathway, which is postulated to be a compensatory route of lymphatic drainage after axillary lymph node dissection (Fig. 4).<sup>8-10</sup> Radial forearm sparing on MRI may further support that a connection from the radial forearm channel to the lateral upper arm channel may protect patients from developing advanced disease.<sup>6</sup>



**FIGURE 4.** Schematic of major posterior forearm lymphatic pathways and their most frequently observed connectivity to compensatory lymphatic pathways in the upper arm.

Along the forearm, fluid infiltration was most frequently seen along the ulnar aspect. The ulnar lymphatic channel is less likely to have a connection to the lateral upper arm pathway and is associated more with the tricipital lymphatic pathway, a compensatory route of lymphatic drainage.<sup>11–13</sup> However, the tricipital channel is less frequently observed, as shown in both in cadaveric dissections and in vivo.<sup>11,14</sup> We therefore propose that compromised or unfavorable anatomic variations of the tricipital pathway may lead to edema at the ulnar forearm. Gravity dependence has been postulated to play a role.<sup>15</sup> However, this would not explain the distribution observed in our study, as we would have also expected a greater accumulation of fluid in the hands and distal extremities, but the hand was essentially spared.

In the distal upper arm, fluid was primarily concentrated posteriorly and occasionally medially. The proximal upper arm was only involved in one case, in which the fluid was present medially. In addition, we propose that the distal posterior upper arm may be a particularly susceptible area to edema because of the relative lack of superficial lymphatic channels present in this area, when compared with the anterior upper arm.<sup>9</sup> This corresponds to our clinic's experience, where patients with very early-stage lymphedema complain of discomfort along the posterior upper arm, just proximal to the olecranon.

We found that the most frequent areas of fluid accumulation in upper extremity lymphedema, mainly the ulnar forearm and the posterior upper arm, align with the trajectory of the tricipital lymphatic pathway, adding support that unfavorable anatomical variations of the tricipital pathway may help explain this most common pattern of fluid distribution. These findings can help guide management of lymphedema at the earliest stage. For example, attention to the ulnar forearm and posterior upper arm during lymphedema surveillance of patients after lymphadenectomy may aid in detecting subclinical disease, resulting in earlier intervention and prevention or mitigation of disease progression. Moreover, it would be useful for lymphedema physical therapists to focus on vulnerable areas of the limb during manual lymphatic drainage in those with mild stage lymphedema. Surgical interventions may be modified to prevent fluid accumulation in vulnerable areas; for example, lymphatic surgeons may consider performing additional lymphovenous bypasses of ulnar forearm channels or transplantation of a lymph node flap to the ulnar aspect of the forearm.

This study is not without limitations. This study was observational, and a small number of patients were evaluated. In addition, the MRI grading system is semiquantitative and thus partially subjective. Finally, all but one patient had secondary lymphedema, and the conclusions may not be applicable to primary lymphedema.

## CONCLUSIONS

In patients with early-stage lymphedema, fluid infiltration was concentrated along the ulnar forearm and the posterior aspect of the distal upper arm, with sparing of the radial forearm. This pattern of edema corresponds to key lymphatic drainage pathways and may be helpful in guiding therapy. This study also reflects the potential use of MRI in corroboration with other imaging modalities to map and understand lymphatic anatomy.

## REFERENCES

- Hespe G, Nitti M, Mehrara B. Pathophysiology of lymphedema. In: *Lymphedema*. Cham: Springer International Publishing; 2015:9–18.
- Greene AK, Goss JA. Diagnosis and staging of lymphedema. *Semin Plast Surg*. 2018;32:12–16.
- Yamamoto T, Matsuda N, Doi K, et al. The earliest finding of indocyanine green lymphography in asymptomatic limbs of lower extremity lymphedema patients secondary to cancer treatment: the modified dermal backflow stage and concept of subclinal lymphedema. *Plast Reconstr Surg*. 2011;128:314e–321e. doi:10.1097/PRS.0b013e3182268da8.
- Kim G, Smith MP, Donohoe KJ, et al. MRI staging of upper extremity secondary lymphedema: correlation with clinical measurements. *Eur Radiol*. 2020;30:4686–4694.
- Kim G, Donohoe K, Smith MP, et al. Use of non-contrast MR in diagnosing secondary lymphedema of the upper extremities. *Clin Imaging*. 2021;80:400–405.
- Kim G, Johnson AR, Hamaguchi R, et al. Breast cancer–related lymphedema: magnetic resonance imaging evidence of sparing centered along the cephalic vein. *J Reconstr Microsurg*. 2021;37:519–523.
- Suehiro K, Morikage N, Yamashita O, et al. Distribution of extracellular fluid in legs with venous edema and lymphedema. *Lymphat Res Biol*. 2016;14:156–161.
- Granoff M, Pardo J, Shillue K, et al. Variable anatomy of the lateral upper arm lymphatic channel: a potential anatomic risk factor for the development of breast cancer related lymphedema. *Plast Reconstr Surg*. [In press].
- Granoff MD, Pardo JA, Johnson AR, et al. Superficial and functional lymphatic anatomy of the upper extremity. *Plast Reconstr Surg*. 2022;150:900–907.
- Leduc A, Caplan I, Leduc O. Lymphatic drainage of the upper limb. Substitution lymphatic pathways. *Eur J Lymphology*. 1993;IV:11–18.
- Friedman R, Bustos VP, Pardo J, et al. Superficial and functional imaging of the tricipital lymphatic pathway: a modern reintroduction. *Breast Cancer Res Treat*. 2023;197:235–242.
- Ciucci J. Derivative lymphatic currents UL, Ciucci, JL - English. In: Nayarit, ed. *Linfedema Del Miembro Superior Postratamiento Del Cancer de Mama*. 2004:29.
- Amore M, Tapia L, Mercado D, et al. Lymphedema: a general outline of its anatomical base. *J Reconstr Microsurg*. 2016;32:2–9.
- Ciucci JL, Vadra GD, Sorocco J. Investigación anatómica del drenaje linfático del miembro superior. Su importancia en la patología traumática. *Rev Asoc Arg Ortop y Traumatol*. 1996;62:544–571.
- Suehiro K, Morikage N, Murakami M, et al. Subcutaneous tissue ultrasonography in legs with dependent edema and secondary lymphedema. *Ann Vasc Dis*. 2014;7:21–27.